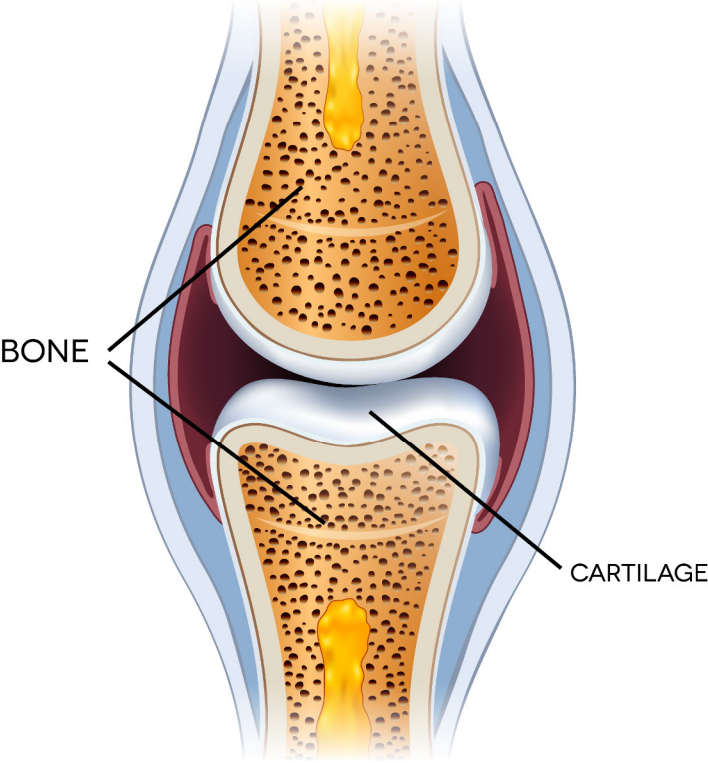


# OSTEOARTHRITIS

NORMAL JOINT



DESTRUCTION OF CARTILAGE

